

High Frequency Oscillations in Ictal Intracranial EEG: Clinical Relevance, Pathophysiology and a Signal Analysis Algorithm for Detection

Kaspar Schindler MD PhD
Department of Neurology, Inselspital
University of Bern





«Chess cannot be taught, it can only be learnt»

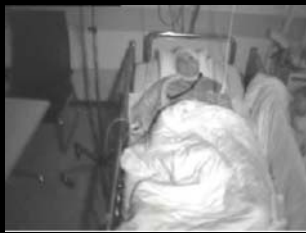Michail Botwinnik
6th World Champion
1911-1995

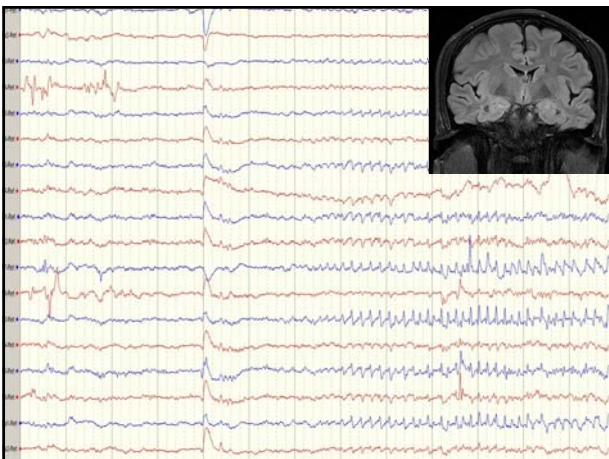
Overview

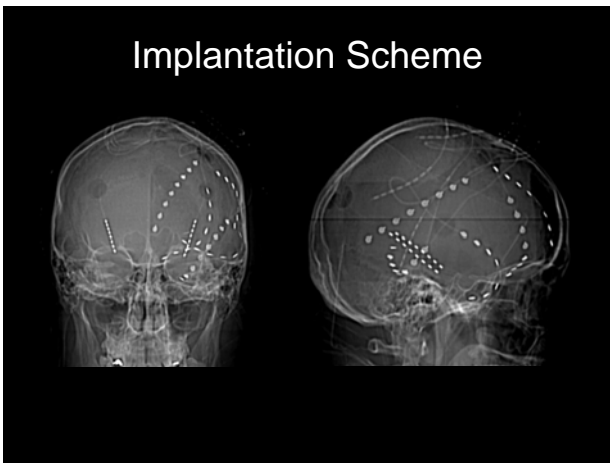
1. Case
2. Pathophysiology
3. EEG Analysis

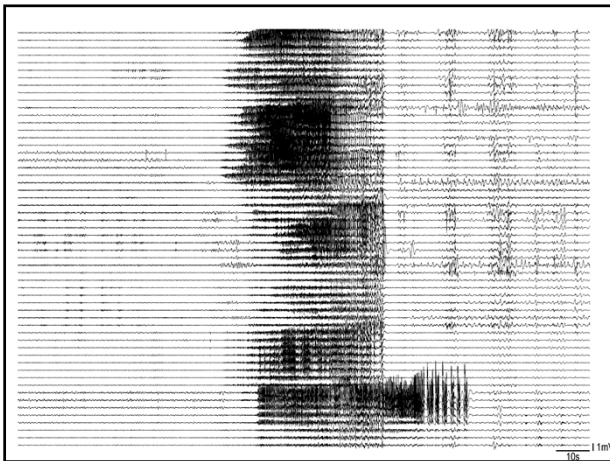
Overview

- 1. Case
- 2. Pathophysiology
- 3. EEG Analysis



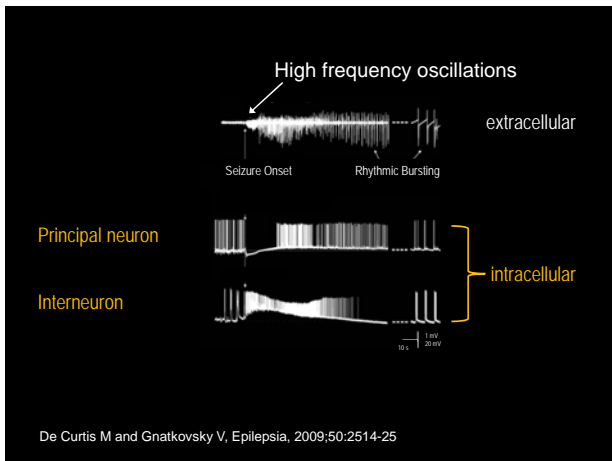


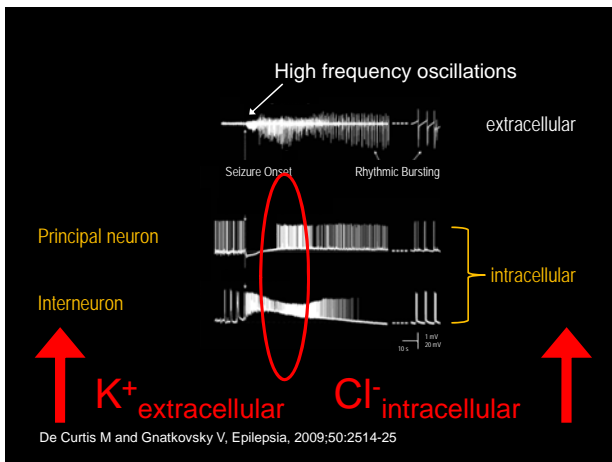


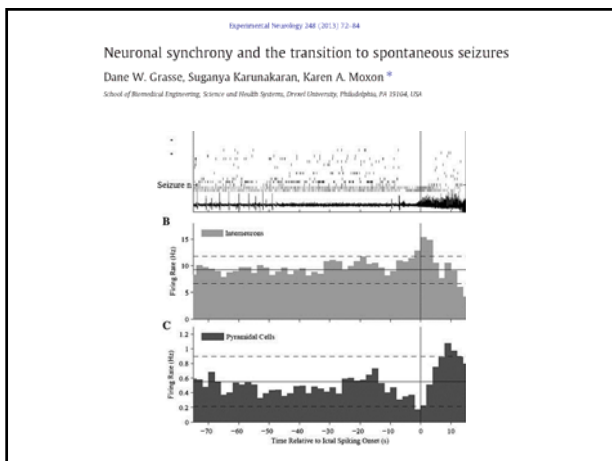


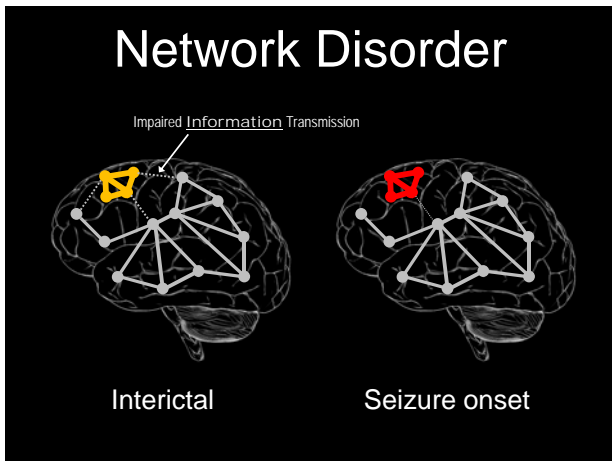
Overview

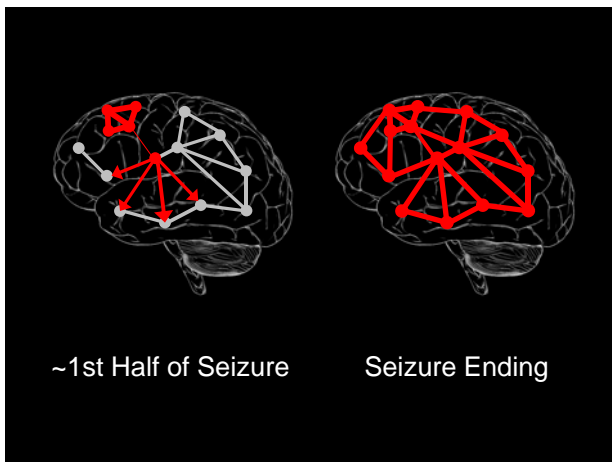
1. Case
2. Pathophysiology
3. EEG Analysis










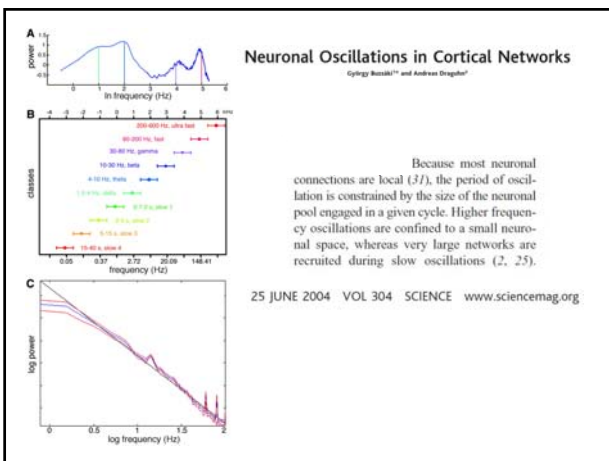


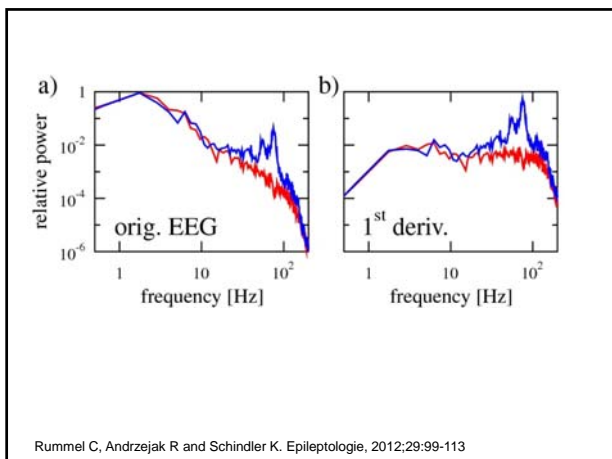


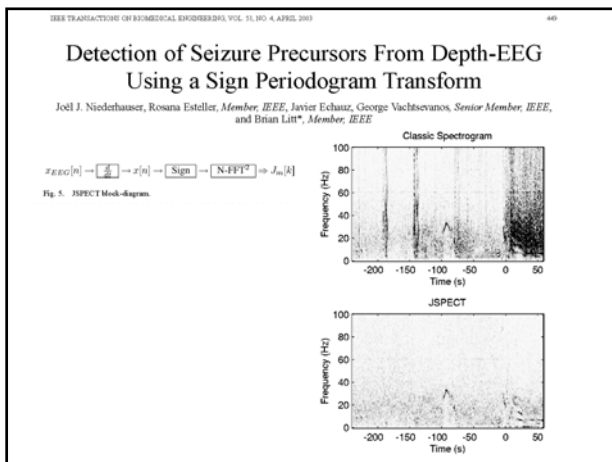
Overview

- 1. Case
- 2. Pathophysiology
- 3. EEG Analysis

univariate



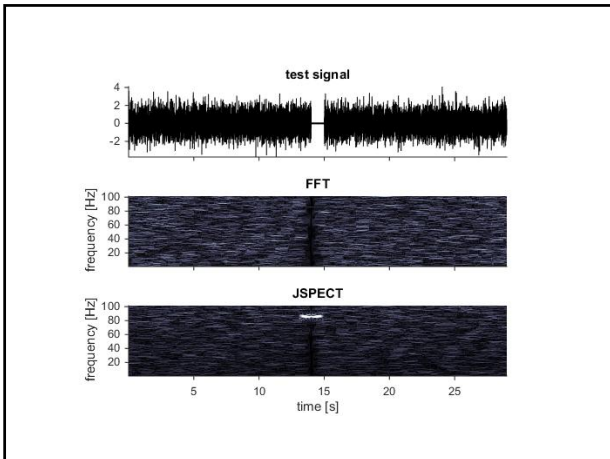


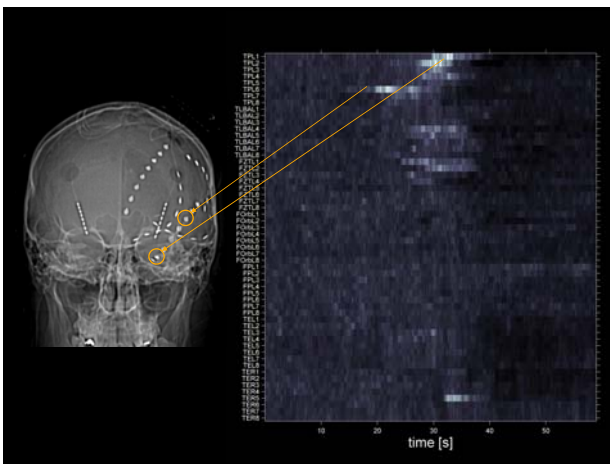


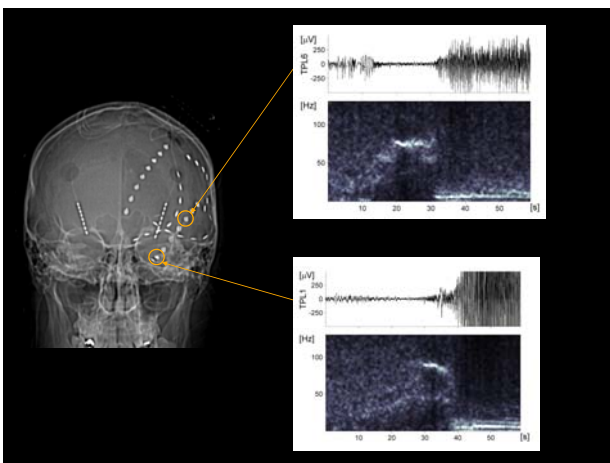
```

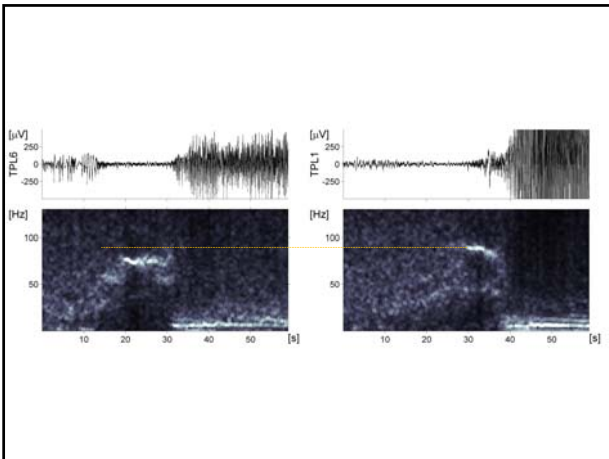
% now we use the JSPECT algorithm; CAVE: carefully note the
% differences
%%%%%%%%%%%%%%%%%%%%%%%%%%%%%%%%%%%%%%%%%%%%%%%%%%%%%%%%%%%%%%%%%%%%%%%%
JSPECTcoil = zeros(101,nSteps); % in this variable the amplitude of the FF

for iStep = 1:nSteps
    dataInMovingWindow = sign(diff(signalA((iStep-1)*dT+1:(iStep-1)*dT+T)));
    ampFFTmovingWindow = abs(fft(dataInMovingWindow));
    JSPECTcoil(:,iStep) = ampFFTmovingWindow(1:101);
end % end for iStep = 1:nSteps
    
```

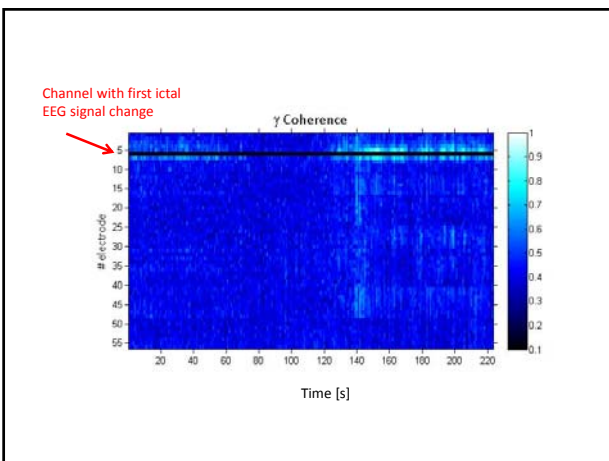


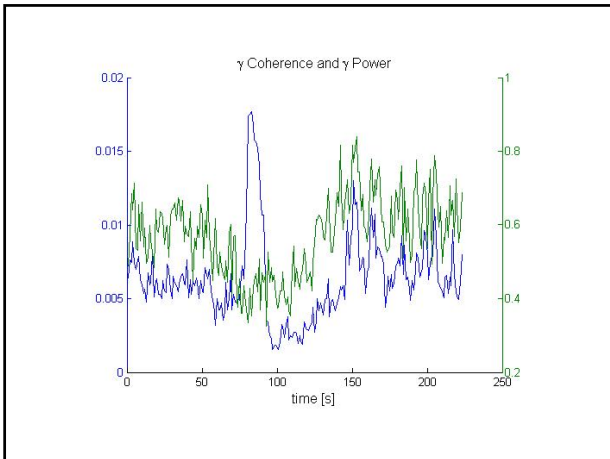


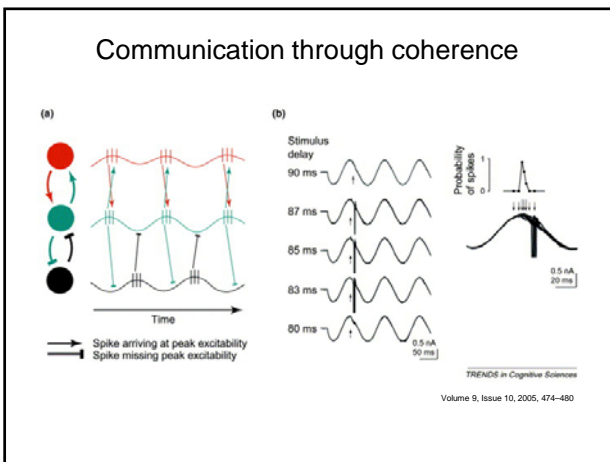




bivariate

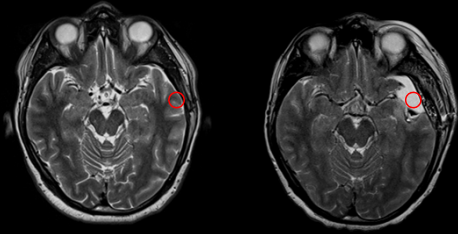






...back to the Case

Temporo-lateral tailored resection



mikexcohen@gmail.com



<http://www.mikexcohen.com/>

End
